

Immunohistochemical study of constitutive neuronal and inducible nitric oxide synthase in the central nervous system of goat with natural listeriosis

Taekyun Shin^{1,3*}, Daniel Weinstock^{1,2}, Marlene D. Castro^{1,2}, Helene Acland^{1,3}, Mark Walter^{1,3}, Hyun Young Kim^{1,3} and H.Graham Purchase^{1,3}

Department of Veterinary Medicine, Institute for Life Science, BK 21, Cheju National University, Cheju 690-756, Korea

¹Pennsylvania Animal Diagnostic Laboratory System

²Center for Veterinary Diagnostics and Investigation, Pennsylvania State University, University Park, PA., U.S.A.

³Pennsylvania Veterinary Laboratory, Harrisburg, PA., U.S.A.

The expression of both constitutive and inducible forms of nitric oxide synthase (NOS) was investigated by immunohistochemical staining of formalin-fixed paraffin-embedded sections in normal and *Listeria monocytogenes*-infected brains of goats. In normal control goats, a small number of neurons showed immunoreactivity of both iNOS and nNOS, and the number of iNOS-positive neurons was higher than the number of nNOS-positive neurons. In natural listeriosis, listeria antigens were easily immunostained in the inflammatory cells of microabscesses. In this lesion, the immunoreactivity of iNOS in neurons was more intense than the control, but nNOS was not. In microabscesses, nNOS was weakly visualized in macrophages and neutrophils, while iNOS was expressed in macrophages, but not in neutrophils. These findings suggest that normal caprine brain cells, including neurons, constitutively express iNOS and nNOS, and the expressions of these molecules is increased in *Listeria monocytogenes* infections. Furthermore, inflammatory cells, including macrophages, expressing both nNOS and iNOS may play important roles in the pathogenesis of bacterial meningoencephalitis in goat.

Key words: nitric oxide synthase, goat, brain, listeriosis

Introduction

Nitric oxide (NO) is a readily diffusible, apolar gas, synthesized from L-arginine by nitric oxide synthase (NOS) [11-13]. The enzyme responsible for NO formation exists in three forms: two constitutive forms, neuronal NOS (nNOS) and endothelial NOS (eNOS), and inducible

NOS (iNOS) [13]. In the central nervous system tissues, all major NOS isoforms are either constitutively expressed or induced by the appropriate stimuli including autoimmune encephalomyelitis [10]. Constitutive NOSs are most important in the initial generation of NO in the central nervous system (CNS), and therefore NO is important for intracellular signaling and neurotransmission [1, 11]. Besides its expected physiological role, NO is likely to be involved in CNS disorders, including experimental autoimmune encephalomyelitis [10], bacterial meningoencephalitis [8], and viral encephalitis [6].

Listeriosis is one of the seasonal CNS diseases in domestic animals including cattle, goats and sheep [2, 6]. *L. monocytogenes* is known as one of the important human pathogens, especially through meat contamination [2]. Goats with natural listeriosis show circling behavior followed, in most cases, by death. Encephalitic lesions are most severe in the midbrain, less severe in the cerebellum, and rarely occur in the cerebrum [3, 4, 14, 17]. Lesions in the brainstem may or may not contain *Listeria monocytogenes* antigens, but characteristically consist of inflammatory cells, including neutrophils, macrophages, and some lymphocytes, suggesting that inflammatory cells play an important role in the brain tissue injury [8, 9]. These cell types are also associated with the secretion of pro-inflammatory cytokines and the generation of toxic free radicals, including nitric oxide, which possibly play roles either in the elimination of infected bacteria or the damage of host tissues.

There is general agreement that a significant increase of iNOS is important in the pathogenesis of natural listeriosis in the brains of cattle and goats [6]. However, constitutive nNOS has not been well elucidated in bacterial meningoencephalitis in goat. The aim of this study was therefore to examine the expression of nNOS in the brain of goats with natural listeriosis, and to compare the

*Corresponding author

Phone: +82-64-754-3363; Fax: +82-64-756-3354

E-mail: shint@cheju.cheju.ac.kr

immunoreactivity of both iNOS and nNOS in the same lesion.

Materials and Methods

Selection of cases

Two cases of goats with natural listeriosis (6 months old and 2.5 years old) (Cases 1 and 2) and two controls (1 and 2 years old) (Cases 3 and 4) were studied. All the brains with natural listeriosis used in this study were from animals submitted for necropsy to the Pennsylvania Animal Diagnostic Laboratory System (PADLS) in Harrisburg, Pennsylvania. In all the selected midbrains, *L. monocytogenes* was confirmed by immunohistochemistry using the antisera described below. Neither direct culture of bacteria nor cold enrichment culture were always successful in isolating *L. monocytogenes* from tissue, although the tissue was positive by immunohistochemistry [7]. Two caprine brains were used as controls. The control animals had no inflammation in the brain by histological examination.

Histopathological examination

Specimens, including brainstem, cerebellum, and cerebrum, were fixed in 10% buffered formalin, embedded in paraffin, sectioned at 4 microns, and stained with hematoxylin and eosin by routine histopathologic techniques. Brainstem sections of paraffin-embedded tissues from animals with characteristic histopathologic lesions of suppurative encephalitis were used for the NOS study.

Antisera and reagents

The antisera used in this study were: rabbit polyclonal antiserum against *L. monocytogenes* (*Listeria* O antiserum poly, serotypes 1 and 4, Difco, Detroit, MI), rabbit anti-gliofibrillary acidic protein (GFAP) (Sigma, St. Louis, MO), rabbit anti-iNOS (Sigma), rabbit anti-nNOS (Sigma). Immunoperoxidase staining was done using the labeled [strept]avidin-biotin (LAB-SA) procedure (Zymed Laboratories, San Francisco, CA).

Immunohistochemistry for *L. monocytogenes*, GFAP, iNOS, and nNOS

Serial sections of midbrain, cerebrum, and cerebellum were deparaffinized and blocked with 3% hydrogen peroxide in distilled water for 10 minutes. After washing with phosphate buffer, sections were blocked, and the primary antisera were reacted for 60 min, followed by biotinylated antisera (Zymed) for 15 minutes and [strept]avidin-biotin peroxidase (Zymed) for 15 minutes. Staining was done using a LAB-SA Kit (Zymed) according to the manufacturers instructions. The dilutions of primary antisera used in this study were as follows: anti-

L. monocytogenes 1 : 1000, anti-GFAP 1 : 1000, anti-iNOS 1 : 100, anti-nNOS 1 : 100, and anti-nitrotyrosine 1 : 1000. For the negative control, primary antiserum was omitted or was replaced with normal rabbit sera (Zymed). All incubations were at 36°C using a Microprobe Staining System (Fisher Biotech, Fisher Scientific, St. Louis, MO). After immunoreaction was complete, sections were counterstained with hematoxylin and mounted with Clearmount (Zymed).

Results

Constitutive expression of nNOS and iNOS in the non-neurological control brain

Both nNOS and iNOS immunoreactivity was recognized in the brain of control goats. No inflammatory cells were found in the brain sections of control animals. The immunoreactivity of iNOS was recognized in the occasional neurons (Fig. 1, A) and choroid plexus cells (Fig. 1, B), but was rare in neuroglial cells. nNOS was also immunoreactive in some neurons (Fig. 1, C) and choroid plexus cells in the same lesion. In the negative control, no immunostaining was seen in sections where primary antiserum was omitted or rabbit anti-*Listeria monocytogenes* antisera substituted (Fig. 1, D). These findings suggest that neuronal cells including neurons, choroid plexus cells and some neuroglial cells may constitutively express both iNOS and nNOS in the non-neurological state.

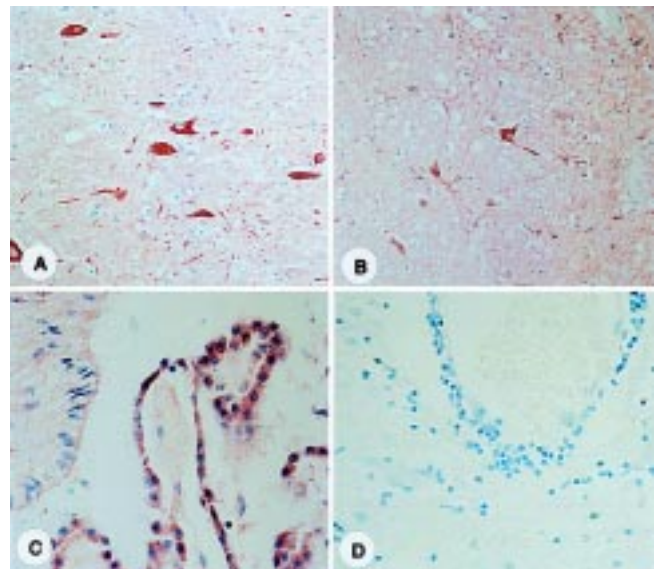


Fig. 1. Immunohistochemical staining of iNOS (A, C) and nNOS (B) in control brains with non-neurological cases. Some neurons constitutively express both iNOS (A) and nNOS (B) in the brainstem. Choroid plexus cells were also positive for iNOS (C). D is a negative immunostaining control which omits primary antisera. A - D, counterstained with hematoxylin. Magnification A and B, $\times 66$. C and D, $\times 132$.

Enhanced expression of nNOS and iNOS in *L. monocytogenes*-infected brain

At necropsy, case 1 (6 months old) showed focal and acute bronchopneumonia, enlargement of the mesenteric lymph nodes and diffuse acute conjunctivitis. Case 2 (2 years old) showed dehydration, myositis and pulmonary edema. Histopathologically, brain tissues from animals with listeriosis showed typical suppurative meningoencephalitis in the midbrain (Fig. 2, A), and occasionally in the cerebellum. The lesions consisted of microabscesses containing neutrophils, and perivascular cuffing of lymphocytes and macrophages. *L. monocytogenes* antigen was commonly found in microabscesses (Fig. 2, B) and perivascular cuffs. Occasionally single positive-staining bacteria were found in the neuronal processes.

Both nNOS and iNOS immunoreactivity were found in a proportion of the neurons in the brainstem and the staining pattern was similar to those of control brains with non-neurological diseases. In the microabscesses, iNOS was recognized in inflammatory cells (mainly macrophages) in the microabscesses, and some astrocytes (identical in

morphology and GFAP immunostaining) surrounding the microabscesses (Fig. 2, C). The iNOS-immunoreactivity in inflammatory cells was largely consistent with that of nNOS (Fig. 2, D). In the white matter adjacent to ventricles, both nNOS- and iNOS-positive glial cells were increased compared with the control animals.

Discussion

This study showed that some neurons in normal control goats expressed both iNOS and nNOS, and that both constitutive nNOS and iNOS in neurons increased when bacterial encephalitis occurred. This is the first study of NOS expression in the goat brain with listeriosis.

The involvement of iNOS in bovine and caprine listeriosis has been reported previously, and the increased expression of iNOS and the resultant NO generation were confirmed in brains with listeriosis and in cultured macrophages from the *Listeria*-affected cattle [6]. This study is in part consistent with the previous study [6], in which some inflammatory macrophages, but neutrophils not, express iNOS in microabscesses. This study reported here are quite different in terms of neuronal staining for iNOS in caprine listeriosis compared with the previous bovine study [6]. We prefer to postulate that the differences are due to the different detection system of immunostaining and different sources of primary antisera. We used a polyclonal antisera (rabbit anti-iNOS, and rabbit anti-nNOS from Sigma).

The increased expression of iNOS in brain cells, i.e., neurons *versus* astrocytes, seen in this study suggests that normal neurons may constitutively express iNOS. We postulate that nitric oxide generated endogenously via either iNOS or nNOS functions as a neuroprotectant against neurotropic injury, because iNOS is known as an endogenous neuroprotectant in traumatic brain injury [18].

The important finding in this study is that nNOS is not only expressed in some neurons, but also in hematogenous macrophages. As far as nNOS expression in neutrophils in pathologic tissues is concerned, this study is a first confirmation, and is supported by the detection of nNOS mRNA in hematogenous cells including macrophages, T cells [15, 16], and neutrophils *in vitro* [5]. The functional role of nNOS in this disease remains to be studied. In addition, Wu et al. [19] reported that nNOS may play a role in the pathogenesis of arthritis and spinal cord inflammation.

In summary, these results suggest that both nNOS and iNOS are constitutively expressed in brain cells, including neurons and some neuroglial cells, and that in the brains of goats with natural listeriosis their expression increases in response to exogenous injury such as *L. monocytogenes* infection. In natural caprine listeriosis, nitric oxide produced by either nNOS or iNOS in neutrophils and macrophages and by brain cells may play an important role

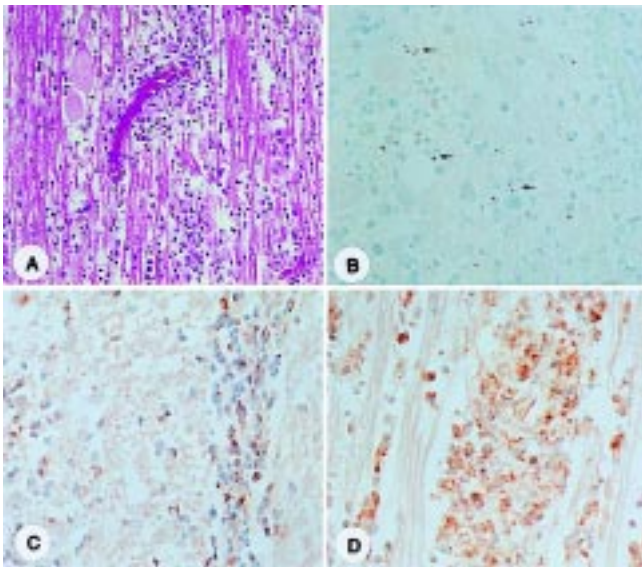


Fig. 2. Histology and immunostaining of caprine brains with natural listeriosis. A: Brain of a goat with listeriosis showing meningoencephalitis. H-E staining, X66. B: Many dot-type bacteria (arrows) with immunoreactivity to anti-*Listeria monocytogenes* antisera were observed in inflammatory microabscesses. Counterstained with hematoxylin. Magnification: $\times 132$. C: Immunohistochemical staining of inducible NOS in the caprine brain with natural listeriosis shows that iNOS immunoreactivity was recognized in neurons, some inflammatory cells in perivascular cuffings. Counterstained with hematoxylin, Magnification: $\times 132$. D: Immunostaining of neuronal NOS in brain sections of goats with natural listeriosis. nNOS immunoreactivity was seen in some inflammatory cells. Some cells show the typical morphology of macrophages in perivascular cuffs and microabscesses. Counterstained with hematoxylin, Magnification: $\times 132$.

in eliminating *Listeria monocytogenes* as well as in the destruction of brain tissue.

Acknowledgments

The authors greatly appreciate Carol Robinson for technical support. The authors also thank Dr. T. W. Jungi, Institute of Veterinary Virology and Animal Pathology, University of Bern, Switzerland for critical discussion of this manuscript. This work is supported by Korea Research Foundation Grant (KRF-2000-041-G00118)

References

1. **Bredt, D.S and Snyder, S.H.** Nitric oxide, a novel neuronal messenger. *Neuron* 1992, **8**, 3-11.
2. **Cooper, J. and Walker, R.D.** Listeriosis. *Vet. Clin. North. Am. Food Anim. Pract.* 1998, **14**, 113-125.
3. **Charlton, K.M. and Garcia, M.M.** Spontaneous listeric encephalitis and neuritis in sheep. Light microscopic studies. *Vet. Pathol.* 1997, **14**, 297-313.
4. **Dramsi, S., Levi, S., Triller, A. and Cossart, P.** Entry of *Listeria monocytogenes* into neurons occurs by cell-to-cell spread: an *in vitro* study. *Infect. Immun.* 1998, **66**, 4461-4468.
5. **Greenberg, S.S., Ouyang, J., Zhao, X. and Giles, T.D.** Human and rat neutrophils constitutively express neuronal nitric oxide synthase mRNA. *Nitric Oxide* 1998, **2**, 203-212.
6. **Hooper, D.C., Ohnishi, S.T., Kean, R., Numagami, Y., Dietzschold, B. and Koprowski, H.** Local nitric oxide production in viral and autoimmune disease of the central nervous system. *Proc. Natl. Acad. Sci. U.S.A.* 1995, **92**, 5312-5316.
7. **Johnson, G.C., Fales, W.H., Maddox, C.W. and Ramos-Vara, J.A.** Evaluation of laboratory test for confirming the diagnosis of encephalitic listeriosis in ruminants. *J. Vet. Diagn. Invest.* 1995, **7**, 223-228.
8. **Jungi, T.W., Pfister, H., Sager, H., Fatzer, R., Vandevelde, M. and Zurbriggen, A.** Comparison of inducible nitric oxide synthase expression in the brain of *Listeria monocytogenes*-infected cattle, sheep and goats and in macrophages stimulated *in vitro*. *Infect. Immun.* 1997, **65**, 5279-5288.
9. **Krueger, N., Low, C. and Donachie, W.** Phenotypic characterization of the cells of the inflammatory response in ovine encephalitic listeriosis. *J. Comp. Pathol.* 1995, **113**, 263-275.
10. **Kim, S., Moon, C., Wie, M., Kim, H., Tanuma, N., Matsumoto, Y. and Shin, T.** Enhanced expression of constitutive and inducible forms of nitric oxide synthase in autoimmune encephalomyelitis. *J. Vet. Sci.*, 2000, **1**, 11-17.
11. **Moncada, S., Palmer, R.M.J. and Higgs, E.A.** Nitric oxide: physiology, pathophysiology, and pharmacology. *Pharmacol. Rev.*, 1991, **43**, 109-134.
12. **Murphy, S., Simmons, M.L., Agullo, L., Carcia, A., Feinstein, D.L., Galea, E., Reis, D.J., Minc-Golomb, D. and Schwartz, J.P.** Synthesis of nitric oxide in CNS glial cells. *T.I.N.S.* 1993, **16**, 323-328.
13. **Nathan, C. and Xie, Q.-W.** Nitric oxide synthases: Roles, tolls and controls. *Cell* 1994, **78**, 915-918.
14. **Otter, A. and Blackmore, W.F.** Observation on the presence of *Listeria monocytogenes* in axons. *Acta Microbiol. Hung.* 1989, **36**, 125-131.
15. **Reiling, N., Ulmer, A.J., Duchrow, M., Ernst, M., Flad, H.D. and Hauschildt, S.** Nitric oxide synthase: mRNA expression of different isoforms in human monocytes/macrophages. *Eur. J. Immunol.* 1994, **24**, 1941-1944.
16. **Reiling, N., Kroncke, R., Ulmer, A.J., Gerdes, J., Flad, H.D. and Hauschildt, S.** Nitric oxide synthase: expression of the endothelial, Ca²⁺/calmodulin-dependent isoform in human B and T lymphocytes. *Eur. J. Immunol.* 1996, **26**, 511-516.
17. **Rouquette, C. and Berche, P.** The pathogenesis of infection by *Listeria monocytogenes*. *Microbiologia* 1996, **12**, 245-258.
18. **Sinz, E.H., Kochanek, P.M., Dixon, C.E., Clark, R.S., Carcillo, J.A., Schiding, J.K., Chen, M., Wisniewski, S.R., Carlos, T.M., William, D., DeKosky, S.T., Watkins, S.C., Marion, D.W. and Billiar, T.R.** Inducible nitric oxide synthase is an endogenous neuroprotectant after traumatic brain injury in rats and mice. *J. Clin. Invest.* 1999, **104**, 647-656.
19. **Wu, J., Lin, Q., Lu, Y., Willis, W.D. and Westlund, K.N.** Changes in nitric oxide synthase isoforms in the spinal cord of rat following induction of chronic arthritis. *Exp. Brain Res.* 1998, **118**, 457-465