

Cecal rupture by *Anoplocephala perfoliata* infection in a Thoroughbred horse in Seoul Race Park, South Korea

Seung-ho Ryu¹, Ung-hok Bak¹, Jun-gyu Kim¹, Hee-jeong Yoon², Hun-su Seo², Jong-tai Kim², Jong-yeol Park², and Chang-woo Lee^{3*}

¹Equine Hospital, Korea Racing Association, Kwachon, Kyonggi-do, 427-070, South Korea,

²Department of Parasitology, College of Veterinary Medicine, Seoul National University, Suwon, 441-744, South Korea,

³Veterinary Medical Teaching Hospital, College of Veterinary Medicine, Seoul National University, Seoul, 151-742, South Korea

Abstract

A 7-year-old Thoroughbred horse was admitted to the Equine Hospital, Korea Racing Association with signs of colic. Based on the size of impactions, the clinical signs, the results of abdominal paracentesis and medical treatment, the prognosis was poor. The horse died 3 hours later following hopeless discharge. At necropsy, the caecum and large colon were fully filled with fecal contents and there was a rupture (10cm in dia) in the latero-ventral caecum. The mucosa of the ileo-caecal and caeco-colic valves appeared to be hyperemic, edematous and ulcerous. There were many tapeworms in the affected mucosa. Histopathologically, lesions included hyperaemia, a deep necrotic inflammatory lesion and ulcers in the mucosa and submucosa of ileo-caecal and caeco-colic valves. One hundred thirty four faecal samples were obtained from 16 stables and submitted to parasitic examination. A total of 4 genera of eggs were recovered: *Strongylus* spp (82.1%), *Anoplocephala perfoliata* (10.5%), *Bovicola equi* (0.7%) and *Parascaris equorum* (1.5%). The major findings in this study are the presence of *A perfoliata* and its suspected association with the colic which led into an eventual caecal rupture. This study indicates the needs for an epidemiological survey of colic that is associated with *Anoplocephala*.

Keywords: horse; cecal rupture; *Anoplocephala perfoliata*; South Korea

Introduction

Several case reports and epidemiological studies have proposed that the equine tapeworm *A perfoliata* is a cause of intestinal diseases such as caecal intussusceptions [1, 3, 8], cecal perforation and peritonitis [2]. *A perfoliata* was presumed to be a significant risk factor for spasmodic colic and ileal impaction in the horse and the risk of spasmodic colic increased with the infection intensity [12]. Duodenal rupture in a nine-month-old colt due to *A magna* has also been reported [7]. Because *A perfoliata* has a predilection to occur at ileo-caecal junction, high infection intensities result in pathology at this site [4, 9], and ileo-caecal diseases of various types are suspected of being tapeworm-related.

To our knowledge, there is no data reporting clinical cases of *A perfoliata* infection in South Korea. The purpose of the present study was to describe the first diagnosed case of caecal rupture caused by *A perfoliata* induced impactions that occurred at the Seoul Race Park, South Korea.

Materials and Methods

Animals and sampling

A 7-year-old Thoroughbred horse was admitted to the Equine Hospital, Korea Racing Association with signs of colic. Prior to admission this horse had hoof crack, so it had received non-steroidal anti-inflammatory drug treatment for 3 days. The horse had received prophylactic anthelmintic treatment quarterly with Oxibendazole (Oximinth Plus).

One hundred thirty four faecal samples (approximately 10% of the horses at the Seoul Race Park, Korea Racing Association) were obtained from 16 stables (about 30% of

*Corresponding author :

Tel: 82-2-880-8677; Fax: 82-2-880-8662

E-mail: anilover@plaza.snu.ac.kr

the stables). One hundred thirty four of Thoroughbred horses were 2 to 8-year-olds. Their origins were from Australia (21 horses, 16%), New Zealand (51 horses, 38%), USA (13 horses, 10%) and South Korea (49 horses, 37%). Their sexes were males (23 horses, 17%), geldings (40 horses, 30%) and females (71 horses, 53%). They had received prophylactic anthelmintic treatment quarterly with Oxibendazole.

Pathological examination

A complete gross and histological pathology examination was performed. Collected tissues were fixed in 10% buffered formalin, embedded in paraffin, sectioned and then stained with hematoxylin and eosin.

Parasitological examination

To identify the recovered tapeworms, two specimens were stained by Mayer's acid carmine for permanent slides and investigated the size and shape of almost all organs of them. Egg identification was done by the flotation method using NaNO₃ in faeces of horses.

Results

Clinical findings

On admission the horse was sweating profusely, appeared anxious and exhibited signs that were suggestive of abdominal pain. Clinical examination revealed: tachycardia (70 beats/min), tachypnea (50 breaths/min) and congested and slightly cyanotic mucous membranes. No intestinal sounds were auscultated in all 4 abdominal quadrants. Rectal palpation identified a concurrent caecum and large colon impactions. Abdominal paracentesis yielded no fluid which suggested that a severe caecum and a large colon impaction existed. Routine medical treatment with i.v. fluids and analgesics failed to alleviate the signs of colic. Based on the size of impactions, the results of the abdominal paracentesis and medical treatment, the prognosis was thought to be poor. The horse died 3 hours later following hopeless discharge because the owner didn't want laparotomy on a racehorse his age.

Pathological findings

A bloody peritoneal fluid and that was feces disseminated over the abdomen from the ruptured caecum were found. The lung was edematous. Gastric ulcers were noted at the margin of the margo plicatus. The gastric and small intestinal contents were bloody. The caecum and large colon were fully filled with fecal contents and there was a

rupture (diameter 10cm) in the latero-ventral caecum. The mucosa of the ileo-caecal and caeco-colic valves appeared hyperemic, edematous and ulcerous. There were many tapeworms that were suspected to be *A perfoliata* present. The remaining findings of the gross necropsy were unremarkable.

Histopathological examination showed deeper necrotic lesions of the affected mucosa which extended into the lymphatic nodules of the submucosa and even into the serosa. These lesions were also infiltrated by neutrophilic and eosinophilic leukocytes.

Parasitological findings

The body sizes of the recovered worms were 14.67 by 7.25mm and 12.5 by 7.15mm, respectively. The sizes of scolexes were 2445.18 by 1978.06µm and 1961.12 by 2324.66µm, respectively. The tapeworms had four suckers in scolex. The average sizes of the suckers were 876.98 and 852.58µm, respectively. The average lengths of the anterior 5 strobila were 78.88 and 115.17µm, respectively and those of the middle 5 strobila were 245.02 and 218.72 µm, respectively and those of posterior 5 strobila were 452.18 and 290.47µm, respectively. *A perfoliata* is reported for the first time in South Korea.

A total of 4 genera of eggs of internal parasites were recovered: *Strongylus* sp (82.1%), *A perfoliata* (10.5%), *B equi* (0.7%) and *P equorum* (1.5%).

Discussion

Colic is the single most important cause of mortality in horses [14]. The equine intestinal cestode *A perfoliata* has been the subject of recent epidemiological and immunological studies because of its suspected association with intestinal disease in the horse [13].

There are several reasons why *A perfoliata* infection has not been reported previously in South Korea. Firstly, clinicians may have neglected the possible relationship between colic with *A perfoliata* infection. Secondly, coprological methods have not been widely applied because prophylactic anthelmintic treatments are usually done regularly and owners and trainers have never complained of a parasitic problem. Thirdly, there was a case of *A perfoliata* infection in a horse that had been imported from another country within one month of arrival (not reported). It was then considered that *A perfoliata* infection did not naturally occur in South Korea but only because the infected horse had been imported. In the present case, the affected horse was born and reared in South Korea for 7

years.

Prior to admission this horse received non-steroidal anti-inflammatory drugs for 3 days because of hoof crack. The non-steroidal anti-inflammatory drugs might have masked the signs of abdominal pain and exacerbated the pre-existing ulcerated site of *A perfoliata* attachment. It is thought that a change in the bowel diameter at the ileo-caecal and caeco-colic junction by the tapeworm attachment caused a local inflammation which developed an impaction and that the caecum was ruptured secondary to the unresolved impaction.

It has been reported that worms can be attached to four regions of the gastrointestinal tract: 17% of the worms were found at the ileo-caecal junction, 81% on the caecal wall, 1.7% in the terminal ileum and 0.2% in the ventral colon. The severity of lesions produced at these sites of attachment is related to the number of worms that are attached. Due to the small area of the ileo-caecal junction, worms at this site are attached in close proximity, which results in a more severe lesion. The major features of the lesions include ulceration, diphtheritic membranes and thickening of the mucosa, submucosa and lamina propria. There is an increase in the number of eosinophils and a decrease in the number of lymphocytes present at the sites of the lesions [9, 16].

Despite of the fact that no relationship established between the tapeworm burden and egg detection, coprological methods had a lower likelihood of diagnosing cestode infection when the horses had less than 100 tapeworms [6], but faecal flotation is likely to be of value in detecting horses that are at risk of clinical disease [15]. Therefore, the faecal flotation method was used to identify the eggs. Eggs of *Strogylus* spp are usually found. One egg of *B equi* and two eggs of *P equorum* were found. But eggs of *A perfoliata* was found in about 10.5% of horses at the Seoul Race Park, South Korea. Prophylactic anthelmintic treatment with Oxibendazole quarterly has failed to control the equine tapeworms.

Spasmodic colic is much more likely to be associated with an *A perfoliata* infection than that which has been detected coprologically. Serological diagnosis revealed an increasing risk of spasmodic colic as the infection intensity increased. No significant association was found between colic and the strongyle egg count. In cases of ileal impaction, a strong association was found between colic and *A perfoliata* when it was diagnosed by coprological means. Serological diagnosis also revealed a strong association that increased with higher levels of infection intensity [12].

Assay of anti-12/13 kDa IgG(T) provided a useful tool for the assessment of *A perfoliata* infection intensity for clinical diagnosis and for epidemiological studies [5, 10, 11, 13]. The assay of anti-12-13 kDa Ig(T) is indicated to survey the prevalence and relationships between colic and *A perfoliata* infection intensity as a follow up study.

Questions remains to be answered. At what infection intensity does *A perfoliata* become a risk factor for colic? Since the present case, a horse was reported to have died from exercise induced pulmonary hemorrhage during training. Necropsy revealed tapeworms and a mild impaction. Could the lung be under much pressure by tapeworm induced impacted bowels piston movement during training or racing?



Fig. 1. Ruptured caecum secondary to unresolved caecal impaction.



Fig. 2. Tapeworms in the ruptured caecum.

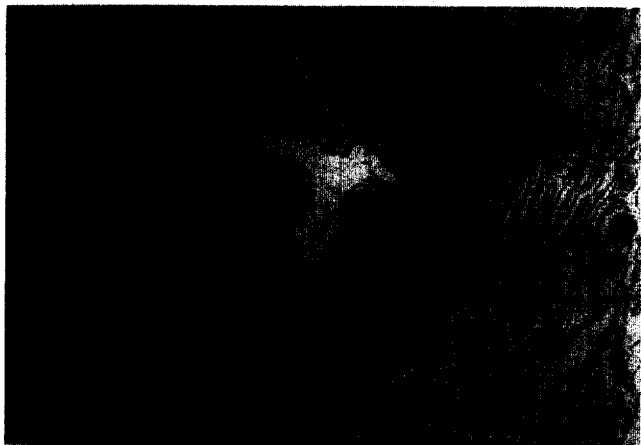


Fig. 3. Histopathological sections from the areas of *A. perfoliata* attachment, lesions include ulceration and lymphadenopathy in the mucosa and submucosa.

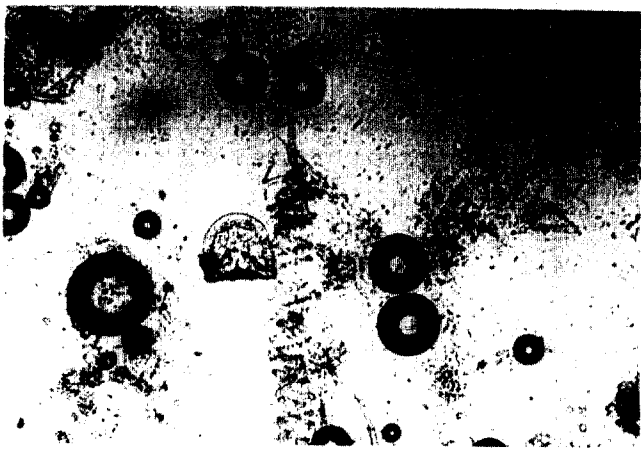

Fig. 4. Round to D shaped egg of *A. perfoliata*.

The major findings of this study conclusively show the presence of *A. perfoliata* in South Korea and the suspected association between colic and the intestinal tapeworm *A. perfoliata*. The results of this study indicate the need for an epidemiological survey of colic and a clinical trial to evaluate the protective role of anti-cestode anthelmintics against colic.

Acknowledgments

The support of the coprological survey done by Sun-joo Yang, Mira Jang and Chang-sook Lee is gratefully acknowledged.

References

1. Barclay, W.P., Phillips, T.N. and Foerner, J.J., 1982. Intussusception associated with *Anoplocephala perfoliata* infection in five horses. *J. Am. vet. Med. Assoc.* 180, 752-3.
2. Beroza, G.A., Barclay, W.P., Phillips, T.N., Foerner J.J. and Donawick W.J., 1983. Cecal perforation and peritonitis associated with *Anoplocephala perfoliata* infection in three horses. *J. Am. vet. Med. Assoc.* 183, 804-6.
3. Edwards, G.B., 1986. Surgical management of intussusception in the horse. *Equine vet. J.* 18, 313-21.
4. Fogarty, U., del Piero, F., Purnell, R.E. and Mosurski, K.R., 1994. Incidence of *Anoplocephala perfoliata* in horses examined at an Irish abattoir. *Vet. Rec.* 134, 515-8.
5. Hoglund, J., Ljungstrom, B.L., Nilsson, O. and Uggla, A., 1995. Enzyme-linked immunosorbent assay (ELISA) for the detection of antibodies to *Anoplocephala perfoliata* in horse sera. *Vet. Parasitol.* 59, 97-106.
6. Meana, A., Luzon, M., Corchero, J. and Gomez- Bautista, M., 1998. Reliability of coprological diagnosis of *Anoplocephala perfoliata* infection. *Vet. Parasitol.* 74, 79-83.
7. Oliver, D.F., Jenkins, C.T. and Walding, J.P., 1977. Duodenum rupture in a nine-month-old colt due to *Anoplocephala magna*. *Vet. Rec.* 101, 80.
8. Owen, R.A., Jagger, D.W. and Quan-Taylor, R., 1989. Caecal intussusceptions in horses and the significance of *Anoplocephala perfoliata*. *Vet. Rec.* 124, 34-7.
9. Pearson, G.R., Davies, L.W., White, A.L. and O'Brien, J.K., 1993. Pathological lesions associated with *Anoplocephala perfoliata* at the ileo-caecal junction of horses. *Vet. Rec.* 132, 179-82.
10. Proudman, C.J. and Trees, A.J., 1996. Correlation of antigen specific IgG and IgG(T) responses with *Anoplocephala perfoliata* infection intensity in the horse. *Parasite Immunol.* 18, 499-506.
11. Proudman, C.J. and Trees, A.J., 1996. Use of excretory/secretory antigens for the serodiagnosis of *Anoplocephala perfoliata* cestodosis. *Vet. Parasitol.* 61, 239-47.
12. Proudman, C.J., French, N.P. and Trees, A.J., 1998. Tapeworm infection is a significant risk factor for spasmodic colic and ileal impaction colic in the horse. *Equine vet. J.* 30, 194-9.
13. Proudman, C.J., Holmes, M.A., Sheoran, A.S., Edwards, S.E. and Trees, A.J., 1997. Immunoepidemiology of the equine tapeworm *Anoplocephala perfoliata*: age- intensity profile and age-dependency of antibody subtype responses. *Parasitology* 114, 89-94.

14. Tinker, M.K., White, N.A., Lessard, P., Thatcher, C.D., Pelzer, K.D., Davis, B. and Carmel, D., 1997. Prospective study of equine colic incidence and mortality. *Equine vet. J.* 29, 448-453.
15. Williamson, R.M., Beveridge, I. and Gasser, R.B., 1998. Coprological methods for the diagnosis of *Anoplocephala perfoliata* infection of the horse. *Aust. vet. J.* 76, 618-21.
16. Williamson, R.M., Gasser, R.B., Middleton, D. and Beveridge, I., 1997. The distribution of *Anoplocephala perfoliata* in the intestine of the horse and associated pathological changes. *Vet. Parasitol.* 73, 225-41.